

MENGO HOSPITAL

PROFORMA INVOICE



P.O.BOX 7161, KAMPALA-UGANDA

Ms NANKYA JOSEPHINE
C/O Madam Florence 0754030907
PACT GROUP

Procedure

Funduplications(laparoscopic

Shs 6,000,000

Six million shillings only.

This is inclusive of theatre fees, drugs, professional fees, laboratory tests, nursing care, bed fee

Date:

29/1/26

Signature:

[Handwritten Signature]

Please note that this is an estimated cost, final invoice may vary depending on final treatment given.

Below are our account details;

Account Title: Mengo Hospital

Account Number: 9030005949091

Bank Name: Stanbic Bank Uganda Limited

Branch: Forest Mall

Swift Code: SBICUGKX

Sort Code: 040147

Currency: Uganda Shillings



For further enquiries, please contact Mr. Edward Kazibwe on 0704065994

MENGO HOSPITAL



GASTROINTESTINAL ENDOSCOPY

Date: Monday 05, January 2026
Procedure: OGD
Surgeon: Dr. Mutambo Samuel
Patient ID: 6515
Admission ID / Case ID : UHID : M250122686
Patient : JOSEPHINE NANKYA
Date of Birth : 20/07/2010
Sex : F
Anatomic Region: Oesophagus, Stomach, Duodenum
Comments:

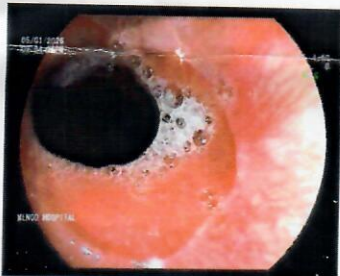
INDICATION :

Long standing epigastric pains x 3 years.

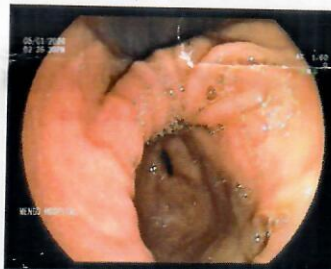
FINDINGS :

GERD grade B, gastritis and hiatus hernia grade IV.

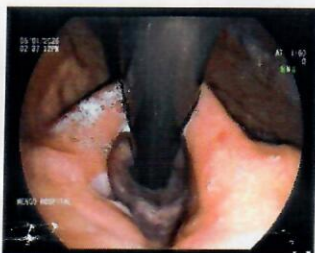Snip biopsies were takenj from the gastric mucosa for histology.



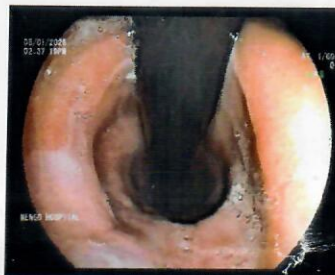og junction



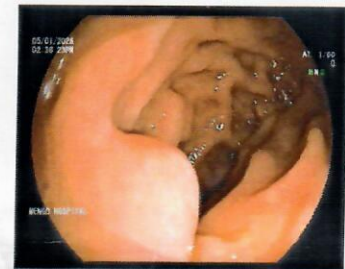antrum



cardia



hiatus hernia



duodenum

Signature:
admin



MENGO HOSPITAL

PATHOLOGY DEPARTMENT

Tel: +256-414 270 620, +256-312 307 100

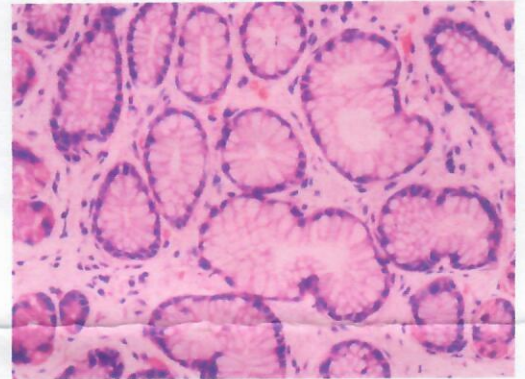
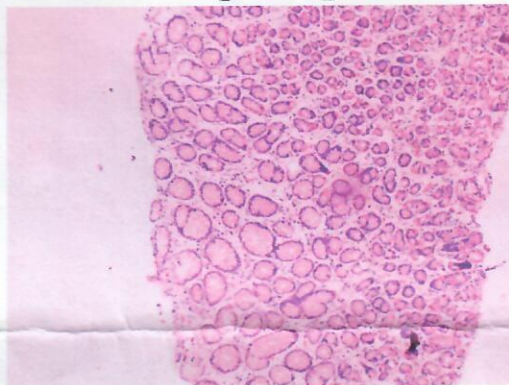
Email: lab@mengohospital.org

HISTOLOGY REPORT

NAME: **JOSEPHINE NANKYA**
SEX/AGE: F/15 HOSPITAL NUMBER: C. DATE: 05/01/2026
ADDRESS REC. NUMBER: R. DATE: 11/01/2026
TEL: LAB. NUMBER: **ML042/26** TIME:
PYH/SURGEON: DR MUTAMBO WARD:

HISTOLOGICAL DIAGNOSIS;

- Mild chronic gastritis of unspecific cause.
- No features of H.pylori infection.
- No malignancy



FINDING(S) :

- H&E sections of gastric mucosa with unremarkable glands and mild diffuse infiltrate of lymphoplasmacytic cells in the lamina propria.

GROSS APPEARANCE

2 whitish brown soft tissue biopsies ms 0.3cm diameter each

NATURE OF SPECIMEN

Gastric mucosa

Dr Kakuba Frank Gahima,
MD. MBChB Mmed Path (Mak)
Anatomical & clinical Pathologist

Printed on 1/11/2026 7:19:09 PM



Mengo Hospital


Mengo Hospital

Sir Albert Cook Road, P.O Box 7161 Kampala, Uganda

Tel : (+256) 0312-307100 | (+256) 0414-270222

Email: medicaldirector@mengohospital.org | https://mengohospital.org

Powered By: ITDose InfoSystems Pvt. Ltd.

Barcode No.	: M145002		Age / Sex	: 15 YRS / Female
Patient NAME	: Miss JOSEPHINE NANKYA			
Sample Coll. Date	: 30-Oct-2025 09:47 AM		Sample Receiving Date	: 30-Oct-2025 09:47 AM
UHID	: M250122686		Reporting Date	: 30-Oct-2025 10:28 AM
IPD No. / Ward	: /		Approved Date	: 30-Oct-2025 10:36 AM
Referring Doctor	: Dr. Ivan Komodo		Status	: Approved Report

DEPARTMENT OF IMMUNOLOGY

Test Name	Status	Result	Reference Range	Unit	Machine
-----------	--------	--------	-----------------	------	---------

H. PYLORI Abs (Blood) (SampleQuality : Good || SampleSuitable : Suitable || Specimen : BLOOD)

Helicobacter Pylori Negative

Interpretation :

H. PYLORI Abs (Blood) : KIT USED:

VAXPERT Ab TEST KIT

Run By: Mr. KAWENYERA LIVINGSTONE

Cross checked by: Miss. NALUWEMBA RESTY

*** End Of Report ***

63500



Mengo Hospital


Mengo Hospital

Sir Albert Cook Road, P O Box 7161 Kampala Uganda

Tel : (+256) 0312-307100 | (+256) 0414 270222

Email: medicaldirector@mengohospital.org | https://mengohospital.org


Powered By: IT:Dose InfoSystems Pvt. Ltd.

Barcode No.	: M145002		Age / Sex	: 15 YRS / Female
Patient NAME	: Miss JOSEPHINE NANKYA			
Sample Coll. Date	: 30-Oct-2025 09:47 AM		Sample Receiving Date	: 30-Oct-2025 09:47 AM
UHID	: M250122686		Reporting Date	: 30-Oct-2025 09:58 AM
IPD No. / Ward	: /		Approved Date	: 30-Oct-2025 10:36 AM
Referring Doctor	: Dr. Ivan Komodo		Status	: Approved Report

DEPARTMENT OF HAEMATOLOGY

Test Name	Status	Result	Reference Range	Unit	Machine
FULL BLOOD COUNT (SampleQuality : Good SampleSuitable : Suitable Specimen : BLOOD)					
WBC	L	3.51	4.23-9.99	10 ³ /ul	BC6200
Neutrophils %	L	37.9	39.6-73.9	%	BC6200
Lymphocytes %	CH	52.4	15.0-45.4	%	BC6200
Monocytes %		7	4.3-12.1	%	BC6200
Eosinophils %		2.6	0.3-6.7	%	BC6200
Basophils %	L	0.1	0.3-1.2	%	BC6200
Neutrophils #	L	1.33	1.45-6.75	Absolute	BC6200
Lymphocytes #		1.84	1.26-3.41	Absolute	BC6200
Monocytes #	L	0.25	0.27-0.81	Absolute	BC6200
Eosinophils #		0.09	0.02-0.51	Absolute	BC6200
Basophils #	L	0	0.01-0.06	Absolute	BC6200
RBC		4.72	3.95-5.13	10 ⁶ /UL	BC6200
HGB		12.4	11.2-15.1	g/dL	BC6200
HCT	L	38.3	39.4-49.5	%	BC6200
MCV		81.1	79.5-95.4	fl	BC6200
MCH		26.2	25.6-32	pg	BC6200
MCHC		32.4	31.0-34.5	g/dl	BC6200
RDW-CV		14.5	11.0-17.3	%	BC6200
RDW-SD		42.6	38.7-47.7	fl	BC6200
PLT		293	173-361	10 ³ /UL	BC6200
MPV	L	8.6	9-12.8		BC6200



Barcode No.	: M145002		Age / Sex	: 15 YRS / Female
Patient NAME	: Miss JOSEPHINE NANKYA			
Sample Coll. Date	: 30-Oct-2025 09:47 AM		Sample Receiving Date	: 30-Oct-2025 09:47 AM
UHID	: M250122686		Reporting Date	: 30-Oct-2025 09:58 AM
IPD No. / Ward	: /		Approved Date	: 30-Oct-2025 10:36 AM
Referring Doctor	: Dr. Ivan Komodo		Status	: Approved Report

DEPARTMENT OF HAEMATOLOGY

Test Name	Status	Result	Reference Range	Unit	Machine
PDW		16	9.0-17.0		BC6200
PCT		0.25	0.17-0.35		BC6200

Run By: Mr. KAWENYERA LIVINGSTONE

Cross checked by: Miss. NALUWEMBA RESTY

**MEDICINE PRESCRIPTION**

Patient Name : Miss JOSEPHINE NANKYA	UHID : M250122686
Age/Sex : 15 YRS/Female	App On : 30-Oct-2025
Doctor : Dr. Ivan Komodo	Visit Type : General OPD
Doc.Speciality : GENERAL	Mobile No. : 0754531217
Panel : CASH GENERAL	

Final Diagnosis :

Sr	ICD Code	ICD Name
1	K29.7	Gastritis, unspecified

R_x

Sr	Name	Dose	Times	Dur.	Route	Qty	Remarks	Prescribed By
*1	Levofloxacin 500mg (Olevo/Levobact) tab	500 Mg	09:00 AM	7 Days	Oral or NG (PO)	7		Dr. KOMODO BENTHSEN IVAN
2	Vonoprazan 20mg (Gastrovon) tab	20 Mg	09:00 AM	2 Week	Oral or NG (PO)	14		Dr. KOMODO BENTHSEN IVAN
3	Betapyn tab (caffeine+Codeine+paracet+doxylamine 50/10/450/5mg)	1 Tabs	06:00 AM,02:00 PM,10:00 PM	3 Days	Oral or NG (PO)	9		Dr. KOMODO BENTHSEN IVAN
4	Relcer gel sy up 180ml	10 ML	06:00 AM,02:00 PM,10:00 PM	7 Days	Oral or NG (PO)	1		Dr. KOMODO BENTHSEN IVAN



MARIE STELLA MEDICARE HOSPICE CENTER

P.O. BOX 146, MITYANA - UGANDA

www.mariestellamedicare.org

+256 772308657

Plot No. 26-28
Bakunga Gardens

Marie Stella
Medicare Hospice Center

Name: Nankya Josephine OPD NO: 3316/2009

Address: Kibukura

Age: 20y Sex: F Wt: Ht: Bmi:

DATE:	CLINICAL NOTES.
27/10/09	PT complains of day sweats at night fever
	Headache
	Exposure 12/7
	She has pain in back as per her 1 yr history of cough - chest pain - dysuria - looks Alex. & stable - sneezing - chest exam ✓
	HA

THIS FORM IS A PROPERTY OF MARIE STELLA MEDICARE HOSPICE CENTER, IT SHOULD BE KEPT BY THE PATIENT NOT BY THE EMPLOYER & BROUGHT AT EVERY VISIT.

280g Bk-ups
H Pgm

urine - Pct - centecox
Pct

hab reporb

B/S : Nonposon

H-pylori: Positive

urine: macro: yellow and slightly

Ucom: pH: 6

Pct: Nil

Glu: Nil

Sh: 1-020

micro: Epithelial cells H seen

Rbc cells H seen

hab: 18,000

2 big cef SB 2 gm ea

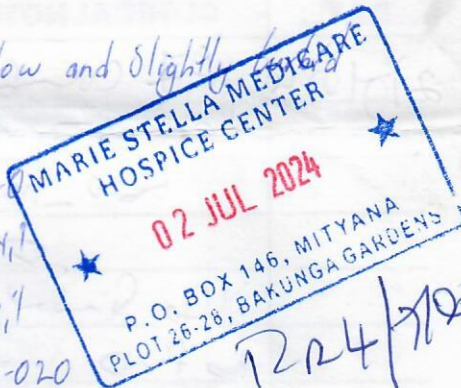15 metro 400 mg

1 cef of 500 mg

1 cef 2 gm 3 gm

1 Pz ampicillin 2 gm

740002
clo pect.



1224/1024



MARIE STELLA MEDICARE HOSPICE CENTER

P.O. BOX 146, MITYANA - UGANDA

Marie Stella
Medicare Hospice Center

📞 www.mariestellamedicare.org

☎ +256 772308657 🏠 Plot No. 26-28
Bakunga Gardens

Name: Nankya, Josephine OPD NO: 278/2
Address: Kitinsule
Age: 13 yrs Sex: F Wt: Ht: Bmi:

DATE:	CLINICAL NOTES.
19/2/24	LMP 8/2022 normal.
	Ab - fever
	- headache
	epididymitis
	noles, cough
	abdominal pain
	vomiting
	ure, meal, bad taste
	9meant
	Throat ok
	Chest - Great
	Blood, R/S
	WBC 15,000

THIS FORM IS A PROPERTY OF MARIE STELLA MEDICARE HOSPICE CENTER, IT SHOULD BE KEPT BY THE PATIENT NOT BY THE EMPLOYER & BROUGHT AT EVERY VISIT.

Lab report

B/D: No mpa soon

widal: Non-reactive

Lab 6000:

~~Stig~~ get 2009 SW
~~Can~~ 15/12/15
~~2~~ 20/12/15
~~Amikacin 1/2 ml~~

148000
 6000
 54000%

46 hari

MARIE STELLA MEDICARE
 HOSPICE CENTER
 19 FEB 2024
 P.O. BOX 146, MITYANA
 PLOT 26-28, BAKUNGA GARDENS



MARIE STELLA MEDICARE HOSPICE CENTER

P.O. BOX 146, MITYANA - UGANDA

www.mariestellamedicare.org

+256 772308657

Plot No. 26-28
Bakunga Gardens

Marie Stella
Medicare Hospice Center

Name: Nankya Josephine OPD NO: 450/5

Address: Kiryukulya

Age: 34 Sex: F Wt: Ht: Bmi: 25.0

DATE:	CLINICAL NOTES.
28/12/24	Review
	ch epigastric
	= headache R/S
	= fever
	no cough
	dm family
	= dysuria
	on 3 week antibiotic
	9 years
	Throat ok
	Chest ok
	Tender on palpation

THIS FORM IS A PROPERTY OF MARIE STELLA MEDICARE HOSPICE CENTER, IT SHOULD BE KEPT BY THE PATIENT NOT BY THE EMPLOYER & BROUGHT AT EVERY VISIT.

Alam: Blood PPS-MP
Widely screen
HTP plus
Lab report

US: No mps seen

Widely: Non-reactive

Acute

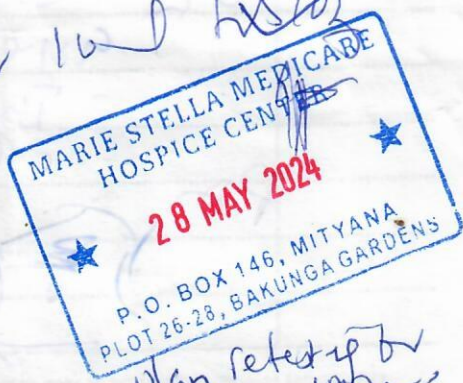m E H-pylori: Positive

Lab 16,000=

21 Sep 2023
22 Sep 2023
23 Sep 2023
24 Sep 2023
25 Sep 2023

9 months
on par

2/2/2023
and meth 2023



Plan refer up by
in 1/1/2024



MARIE STELLA MEDICARE HOSPICE CENTER

P.O. BOX 146, MITYANA - UGANDA



www.mariestellamedicare.org



+256 772308657



Plot No. 26-28
Bakunga Gardens

Marie Stella
Medicare Hospice Center

Name: Nankya Daphine OPD NO: 440/12024

Address: 1572nd St

Age: 610 Sex: F Wt: Ht: Bmi:

DATE:	CLINICAL NOTES.
2/6/24	Report of the patient while on Vigabatrin
	<ul style="list-style-type: none"> 1) Cop A - 500mg 2) Cop B - 1000mg 3) Cop C - 200mg 4) Cop D - 50mg
	12/1/2024
	10/6/24 to 18/06/24

MARIE STELLA MEDICARE HOSPICE CENTER
 02 JUN 2024
 P.O. BOX 146, MITYANA
 BAKUNGA GARDENS

THIS FORM IS A PROPERTY OF MARIE STELLA MEDICARE HOSPICE CENTER, IT SHOULD BE KEPT BY THE PATIENT NOT BY THE EMPLOYER & BROUGHT AT EVERY VISIT.



MARIE STELLA MEDICARE HOSPICE CENTER

P.O. BOX 146, MITYANA - UGANDA

📍 www.mariestellamedicare.org

☎ +256 772308657 📍 Plot No. 26-28
Bakunga Gardens

Marie Stella
Medicare Hospice Center

Name: Nankya Josephine OPD NO:

Address: Katunguru

Age: 13yrs Sex: F Wt: Ht: Bmi:

DATE:	CLINICAL NOTES.
15/6/2024	<p>Reports,</p> <p>lost her eye plus as well as diarrhea.</p> <p>clinically found to have dysphagia meanwhile she is receiving oral and IV fluids on the 15/6/2024 with O2Cp 2ml/min and OTs given as per e</p>

MARIE STELLA MEDICARE
HOSPICE CENTER
15 JUN 2024

THIS FORM IS A PROPERTY OF MARIE STELLA MEDICARE HOSPICE CENTER, IT SHOULD BE KEPT BY THE PATIENT NOT BY THE EMPLOYER & BROUGHT AT EVERY VISIT.

ME & YOU MEDICAL CENTRE (MYMC)



Located: Mityana Kitinkokola, 250mtrs from Tamac Rd

Email: meandyouhealthcare682@gmail.com

Tel: 0707354495 / 0774969702

DISCHARGE FORM

Name: Fina Naulaga Sex: Female wt: 49kg

Age: 14yrs Address: Kitinkokola Tel: 0789648078

Next of Kin: Mulindegi

Date of Admission: 13/3/2014 Date of Discharge: 17/3/2014

Patient's condition/Diagnosis: Severe Rash

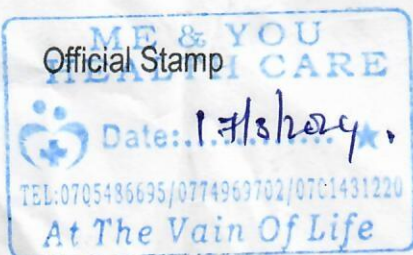Hx/Rx: ✓ Omeprazole 20mg bd 31x - by B'smith 20/1/14
✓ Cef by bd 31x
✓ Meth 500mg bd 31x
✓ pain by tabs 21x
✓ 1000mg 1h O.S.L in 24hrs / 1m tramadol 100mg tabs

Discharge Rx: ✓ Omeprazole 20mg ad x 10d
✓ Meth 500mg tabs 5d
✓ Cef 500mg bd 5d
✓ pain by tabs 3x

Condition on discharge: Fair and fit for discharge

BP: 11 PR: 70 TEMP: 36.1°C RR: 18/min

Next Visit: after two days



Signature: [Handwritten Signature]

"At the vine of life"

Gynecology(1/1) - 22/03/2024

Name: NANKYA JOSEPHINE
 ID: 20240322-125849-BD4E

DOB: Operator: Age: 13 Years Gender: Female
 Ref Physician: BSA

Report Type: Abdomen

2D Measurements	Value	1	2	3	Method
Liver	10.72cm	10.72			Avg
Spleen	10.91cm	10.91			Avg
Right Kidney					
Renal L	10.70cm	10.70			Avg
Renal H	3.89cm	3.89			Avg
Left Kidney					
Renal L	11.16cm	11.16			Avg
Renal H	4.91cm	4.91			Avg

Comments

Print Print View Export Image Select Save Comment Load Comment OK Cancel

Gynecology(1/1) - 22/03/2024

Name: NANKYA JOSEPHINE
 ID: 20240322-125849-BD4E

DOB: Operator: Age: 13 Years Gender: Female
 Ref Physician: LMP

Report Type: Gynecology

2D Measurements	Value	1	2	3	Method
Uterus					
UT L	7.47cm	7.47			Avg
UT W	3.26cm	3.26			Avg
UT H	3.11cm	3.11			Avg
UT Vol	63.87cm ³				
	15.84cm				

DOCHUB MEDICAL CHAMBERS

MITYANA MUNICIPALITY, STATION ROAD

CONTACT: 0788921122/ 0701532542

P.O. box 180088

Email.dochubmedicalchambers@gmail.com

ULTRASOUND REPORT

NAME: Nankya Josephine AGE: 13yo SEX: F

ADDRESS: Mityana DATE: 22/03/24

BRIEF HISTORY/INDICATION:

Routine abdominal scan.

FINDINGS: The liver appears normal in size, shape and echo-pattern. It measures 10.72cm.

The gall bladder and pancreas appear normal.

The spleen appears normal in shape, size and echo-pattern. It measures 10.91cm from pole to pole.

Both kidneys appear normal with normal cortical medullary differentiation.

The urinary bladder is well distended with echo-free urine. Normal wall thickness.

There is gas accumulation in the bowels and irregular inner wall lining noted at the level of the stomach.

No ascities or lymphadenopathy.

The uterus appears normal in shape, size and echo-pattern.

There is a well defined thin walled cystic mass seen in the right ovary measuring 2.09cm in diameter.

IMPRESSION:

① Gastritis

② Dominant follicle in right ovary

[Signature]

BRINE KEBIRUNGI

SONOGRAPHER



MARIE STELLA MEDICARE HOSPICE CENTER

P.O. BOX 146, MITYANA - UGANDA

www.mariestellamedicare.org

Marie Stella
Medicare Hospice Center

+256 772308657



Plot No. 26-28
Bakunga Gardens

Name: Nankya Sophie OPD NO: 738110

Address: KITIKOVU

Age: 13yrs Sex: F Wt: Ht: Bmi:

DATE:	CLINICAL NOTES.
20/10/2017	Referral no headache - sleepless no fever - chest pain - muscle aches - chest pain - weakness - chest pain
9/11/17	Referral - chest pain - weakness - chest pain

THIS FORM IS A PROPERTY OF MARIE STELLA MEDICARE HOSPICE CENTER, IT SHOULD BE KEPT BY THE PATIENT NOT BY THE EMPLOYER & BROUGHT AT EVERY VISIT.

Lab reports

BUS: No mps seen

Widal: Non-reactive

Urine: Macro: Yellow and slightly turbid

Chem: pH: 6.5

Prot: Nil

Glucose: Nil

SG: 1.020

Micro: Epithelial cells Ht seen

Lab 11,000 =

- ① Big granular / 6-9 / 15-20
- ② The cells were seen at 5
- ③ plenty of red granules
- ④ Cap of 2-3 / 3-4

blown in pair



M E



The Republic of Uganda

MITYANA GENERAL HOSPITAL

HMIS FORM 052: INPATIENT DISCHARGE FORM

Ward: Paed Inpatient No. 2138

Name: Nankya Betty Josephine Age: 12 yrs Sex: M F

Address: Kitinkukule

Date of Admission: 20/3/23 Date of Discharge: 20/3/23

Status on Discharge:

Provisional Diagnosis: Final Diagnosis: Acute PUD

Clinical Presentation of Patient:
FGC, afebrile, (JACCOLD)

Summary of intervention given (investigation, treatment and surgical procedure)
* Tabs Metronidazole 400mg 8^o x 10/7.
* Tabs Clarithromycin 500mg O.D x 5/7.
* Tabs Omeprazole 40mg B.D x 14/7.
- Tabs PCM 1g 8^o x 2/7.
* Tabs Mebendazole 400mg stat.

Recommendation on Discharge:

Name of Discharging Officer: Dr. Kisira Joel Designation: Dr.

Date of follow-up: PRN

Place: MGH

Please come with this form at your next visit to the Health Unit



BMK MEDICAL LABORATORY MITYANA

Tel Line: 0706-429993, 0755891834, 0774-199811

Thoban Road Mityana Municipality-Central Division (Opposite Mityana General Hospital Main Gate)

Laboratory Results Report

Report Laboratory test results

For: BMK1517

6

Patient names: NANKYA
JOSEPHINE

Age: 12

sex: female

Tel:

Health Facility: Mityana hospital

Requested by: DR FOSCA

Date:
2023-03-21

Tel:

Specimen Type: Serum

Collected: 2023-03-21 12:00


Received: 2023-03-21 12:00

Test	Result	Ref Range	Date
H. pylori Serum Antibody- RDT	<u>Positive</u>	N/A	2023-03-21

Comments: As with all diagnostic tests, the final diagnosis should not be based on the results of single tests, but should be based on correlation of test results with other clinical findings.

Result Reviewed Sign: [Signature]

Date:



Result Authorized Sign: [Signature]

Date:

CBC, HB estimation, Hepatitis B, HIV, Renal/Liver/Heart/Pancreas Function Tests, (RFTs), Hormonal Profiles, Lipid Profiles, Consultancy in Laboratory Systems



BMK MEDICAL LABORATORY MITYANA

Tel Line: 0706-429993, 0755891834, 0774-199811

Thoban Road Mityana Municipality-Central Division (Opposite Mityana General Hospital Main Gate)

Laboratory Results Report

Report **Laboratory test results**

For: BMK1517

1

Patient names: NANKYA
JOSEPHINE

Age: 12

sex: female

Tel:

Health Facility: Mityana hospital

Requested by: TUMWINE

Date:
2023-03-21


Tel:

Specimen Type: Whole blood

Collected: 2023-03-21 08:53

Received: 2023-03-21 08:53

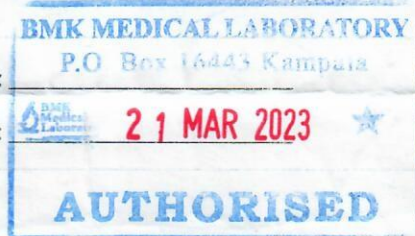Test	Result	Ref Range	Date
ABO and Rhesus Blood Grouping	ABO Blood Group: A		
	Rhesus Factor-D: POSITIVE	N/A	2023-03-21
CBC (Complete Blood Count)	See attached copy	N/A	2023-03-21

Result Reviewed Sign: 

Date:

Result Authorized Sign: 

Date:

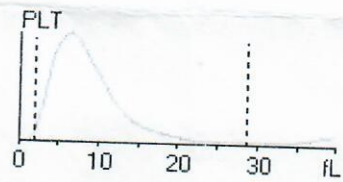
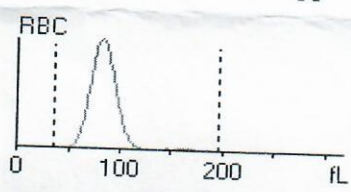

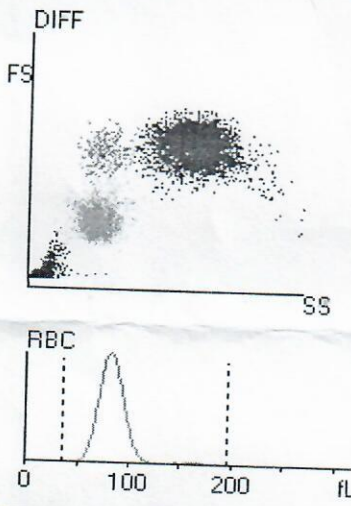


CBC, HB estimation, Hepatitis B, HIV, Renal/Liver/Heart/Pancreas Function Tests, (RFTs), Hormonal Profiles, Lipid Profiles, Consultancy in Laboratory Systems

BMK MEDICAL LABORATORY-MITYANA

Patient ID: BMK15171 Last Name: NANKYA First Name: JOSEPHINE Gender: FEMALE
 Age: 12Year Birthday: Dept.: MITYANA... Bed No.:
 Sample ID: 468 Run Time: 03-21-2023 08:15 Mode: WB CBC+DIFF

Parameter		Result Unit	Ref. Range	
WBC		8.19 x10⁹/L	4.00 - 12.00	<div style="border: 1px solid black; padding: 2px; margin-bottom: 5px; text-align: center;">WBC Flag</div> <div style="border: 1px solid black; padding: 2px; margin-bottom: 5px;">WBC Abn scattergram</div> <div style="border: 1px solid black; padding: 2px; margin-bottom: 5px; text-align: center;">RBC Flag</div> <div style="border: 1px solid black; padding: 2px; margin-bottom: 5px; text-align: center;">PLT Flag</div>
Neu%		62.0 %	50.0 - 70.0	
Lym%		33.3 %	20.0 - 60.0	
Mon%		3.9 %	3.0 - 12.0	
Eos%		0.5 %	0.5 - 5.0	
Bas%		0.3 %	0.0 - 1.0	
Neu#		5.08 x10 ⁹ /L	2.00 - 8.00	
Lym#		2.73 x10 ⁹ /L	0.80 - 7.00	
Mon#		0.32 x10 ⁹ /L	0.12 - 1.20	
Eos#		0.04 x10 ⁹ /L	0.02 - 0.80	
Bas#		0.02 x10 ⁹ /L	0.00 - 0.10	
RBC	H	5.47 x10¹²/L	3.50 - 5.20	
HGB		14.1 g/dL	12.0 - 16.0	
HCT		0.468	0.350 - 0.490	
MCV		85.6 fL	80.0 - 100.0	
MCH	L	25.8 pg	27.0 - 34.0	
MCHC	L	30.2 g/dL	31.0 - 37.0	
RDW-CV		12.7 %	11.0 - 16.0	
RDW-SD		44.9 fL	35.0 - 56.0	
PLT		282 x10⁹/L	100 - 300	
MPV		8.1 fL	6.5 - 12.0	
PDW		15.8	9.0 - 17.0	
PCT		2.29 mL/L	1.08 - 2.82	



BMK MEDICAL LABORATORY
 P.O. Box 16443 Kampala

21 MAR 2023

AUTHORISED

Deliverer: BMK 1 Operator: BMK LAB Validator:
 Draw Time: 03-21-2023 08:15 Delivery Time: 03-21-2023 08:15 Print Time: 03-21-2023 08:34:47
 Remarks:

*This result applies to this sample only



The Republic of Uganda

MITYANA GENERAL HOSPITAL

HMIS FORM 052: INPATIENT DISCHARGE FORM

Ward: PEAS Inpatient No. 1955

Name: NANKYA JOSEPHINE Age: 12 1/2 Sex: F

Address: Kitinkokoolo

Date of Admission: 28/02/2023 Date of Discharge: 01/03/2023

Status on Discharge: Today Reports Improvement

Provisional Diagnosis: PUD Final Diagnosis: PUD

Clinical Presentation of Patient:

Noted above patient being managed for PUD.
Today reports improvement

Summary of intervention given (investigation, treatment and surgical procedure)

Discharged home.

1) Tabs Metronidazole 400mg Tds x 2/52 (84)

2) Tabs Clarithromycin 500mg b.d x 2/52

3) Caps Amoxil 1g b.d x 2/52 (84)

4) Tabs Esos 40g b.d x 3/52 (10 days) + 2 days

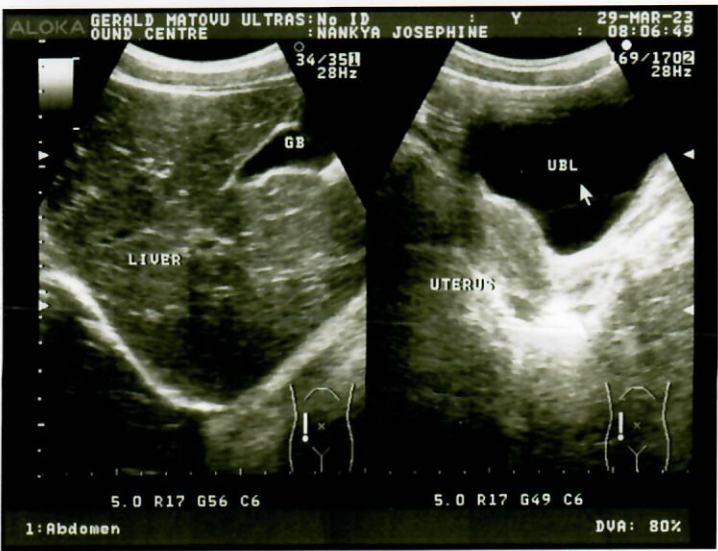
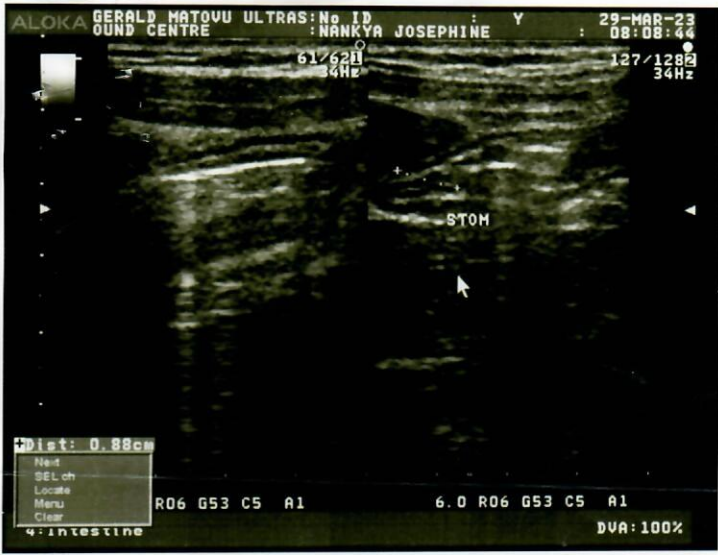
Recommendation on Discharge: RIV PRN

Name of Discharging Officer: Dr. Kisira Joel Designation: Dr.

Date of follow-up: PRN

Place: OPD

Please come with this form at your next visit to the Health Unit





**GERALD MATOVU ULTRASOUND CENTRE
MITYANA**

Email; matovugeraldus@yahoo.com. Tel; 0789-098988

ULTRA SOUND REPORT

=====

NAME: NANKYA JOSEPHINE AGE 12YRS SEX: F

=====

ADDRESS: K'KOLA DATE: 29/3/2023

=====

FINDINGS.

Ultrasound evaluation reveals a thickened hypoechoic wall of the stomach measuring (8.8) mm.

The stomach rugae are prominent.

Bowel peristalsis is normal. No ascites seen.

No enlarged lymph nodes seen.

Liver, Spleen, kidneys, gallbladder and pancreas appear normal.

Pelvic organs appear normal.

Conclusion.

Features are of chronic gastritis.

MATOVU GERALD
MEDICAL IMAGING TECHNOLOGIST

Psalms: 18



DOCHUB MEDICAL CHAMBERS

Email: info@dochubmedicalchambers.com

MITYANA - STATION ROAD

Tel: 0788 921122

5485

PATIENT'S LAB REQUEST FORM

Date: 22/3/24

Name: Filia Minkya

Address: Kambakula

Patient's number: Pt Tel: Body weight:

DIAGNOSIS TREATMENT NOTES

AGE: 4yrs SEX: F

Clinical History and Laboratory Test(s) Required

Specimen / Material

- (1) Blood
- (2) CFC
- (3) Urine
- (4) Stool
- (5) Sputum
- (6) Scan

Clinical Notes

Examination Required: - Stool Analysis
 - Abdominal palpation
 Lab on in to stool

Lab Report: - CBC

Stool analysis:
 Macroscopy: Brown and formed
 Microscopy: No ova, cyst seen.

Technician Signature

"Where Care Comes First"

Stool analysis

Macroscopy: Brown and Formed.

Microscopy: No ova, cyst seen.

Patient's name: _____

DIAGNOSIS TREATMENT NOTES

AGE: _____

SEX: _____

Clinical History and Laboratory Test(s) Reported

Specimen(s) Requested

- (1) Blood
- (2) O/C
- (3) Stool
- (4) Urine
- (5) Sputum
- (6) CSF

Specimen(s) Received

Stool / Urine -
 Microscopy / Culture -
 Report on 10.10.18
 O/C -

Urine analysis: Macroscopy Brown and formed

Microscopy: No ova, cyst seen.

Technician Signature

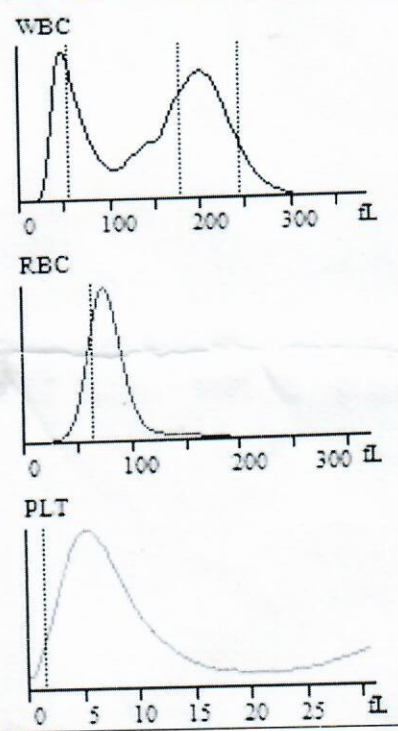
When Case Closed

DOCHUB MEDICAL CHAMBERS

....

Name: NANKYA...	Dept.:	Patient Type:	Sample ID: 3
Gender:	Sickroom:	Patient ID: 3	Diagnosis:
Age: 14 Year	Bed No.:	Sample Type:	Test Time: 3/22/2024 11:52 AM

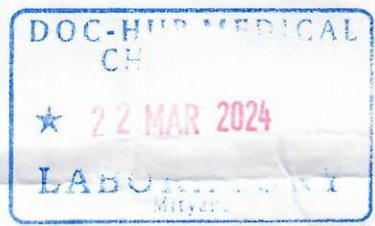Parameter	Result	Unit	Ref.range
WBC	L 3.9	10 ⁹ /L	4.0-10.0
Lymph#	1.2	10 ⁹ /L	0.8-4.0
Mid#	0.2	10 ⁹ /L	0.1-1.5
Gran#	2.5	10 ⁹ /L	2.0-7.0
Lymph%	30.6	%	20.0-40.0
Mid%	5.9	%	3.0-15.0
Gran%	63.5	%	50.0-70.0
RBC	4.89	10 ¹² /L	3.50-5.50
HGB	13.1	g/dL	11.0-18.0
HCT	40.8	%	37.0-54.0
MCV	83.5	fL	80.0-100.0
MCH	26.9	pg	27.0-34.0
MCHC	32.2	g/dL	32.0-36.0
RDW-CV	15.2	%	11.0-16.0
RDW-SD	41.8	fL	35.0-56.0
PLT	268	10 ⁹ /L	150-450
MPV	8.1	fL	6.5-12.0
PDW	15.4	%	15.0-17.0
PCT	0.216	%	0.108-0.282



Delivery Time: 3/22/2024 12:00 AM
Print Time: 3/22/2024 12:10:44 PM

Deliverer:
Tester: admin

Validator:
***The result applies to this sample!**





Reproductive Health Uganda

MEDICAL FORM

Name of Clinic: RHU Nankya Josephine Clinic Contact: 0773725268

Client Name: Nankya Josephine AGE: 14 Sex: F M

Client Contact: 0754531217 Next of Kin Contact: MULINDWA Jose

Date: 4/8/25 Unique ID Number: (from the Daily Register)

Client's Medical History

She came complaining of epigastric pain nausea loss of appetite and severe headache.

Brief Examination

Ab; Ultra sound scan

Diagnosis PUD

Treatment Notes

IV metro 500mg bd x 2/7
IV Cep 2g o.d x 3/7 then
Ths Cefixime 400mg o.d 3/7
Ths metro 400mg tds x 7/7

PROVIDER'S NAME: Nazziwi Ritah Signature: [Signature]



Reproductive
Health Uganda

MITYANA--0700390224

ULTRASOUND SCAN REPORT

NAME: Nankya Josephine
AGE: 14yrs
SEX: F
ADDRESS: mityana
DATE: 08/07/ 2025
EXAMINATION: Pelvic SCAN
INDICATION: c/o abdominal pains

FINDINGS:

With a 2.5-5.0MHZ transducer probe in B-mode, the Pelvic region was scanned.

The uterus appears normal in size, shape and echo pattern measuring (7.4x5.5x3.4) cm. No myometrial masses noted.

The endometrium appears thick and echogenic . it measures 0.8cm.

The cervix is normal and devoid of masses. Both ovaries are normal, No tubovarian masses seen.

Both adnexa are normal.

No fluid seen in Pouch of Douglas.

There is a thickened bowel loop segment noted at the epigastrium. There is excessive intraluminal bowel gas noted within the abdomen .

Liver is normal in shape, size and echotexture with no focal lesions.

Gallbladder is well-distended with anechoic bile

Both kidneys are normal in shape, size and corticomedullary differentiation with no calculi.

The urinary bladder appears adequately distended by echofree urine.

Spleen & pancreas are normal in shape, size and echotexture.

No ascites/intra-abdominal masses/enlarged lymph nodes seen.

CONCLUSION:

- Gassy abdomen ; PUD most likely

.....
K Joshua
Med imaging Tech